

In this issue we review:

- Vistafix prostheses in patients with head and neck cancer.
- Vistafix studies and articles.

## Vistafix® improves cosmetic outcomes after cancer surgery.

*Post-operative facial disfigurement may occur in patients with head and neck cancer. A Vistafix bone-anchored prosthesis rebuilds both the site and the patient's self-image.*

### Treatment of head and neck cancer

Radiation, chemotherapy, and/or surgery are used to treat head and neck cancer, but the treatment may disfigure and cause self image difficulties for the patient<sup>(1)</sup>. That's why cosmetic repairs may be just as important to the patient as the treatment itself<sup>(2)</sup>. While plastic surgery offers a multitude of techniques to reconstruct facial defects, multiple procedures may be required to achieve the desired result, and those results may be uncertain<sup>(2)</sup>. Plastic surgery may also prove problematic for patients that are slow to heal, such as the elderly, or those with diabetes. Vistafix may provide better results than plastic surgery when restoring facial defects<sup>(3)</sup>.

### Applying a Vistafix prosthesis

Vistafix is a facial prosthetic treatment that uses bone-anchored titanium implants as a permanent means to attach an individual prosthesis. Prior to surgery, a Vistafix prosthesis is planned with the anaplastologist to ensure that the implants are optimally positioned. Once the implants have been placed and have osseointegrated, a bar construction or magnets are mounted on the implants. An imprint of the implant area is made and an acrylic plate with clips or magnets to retain the prosthesis is then made. Onto this plate the silicone prosthesis is moulded from a wax model. On average, time from surgery to finished prosthesis is around 3 months, depending on the time needed for the implants to osseointegrate.

### Aesthetic outcome

The cosmetic result is the most important outcome measure of the procedure. As shown in the images on the right, realistic outcomes are typically achieved with Vistafix.

### Patient satisfaction

Study results show a high degree of patient satisfaction with Vistafix prostheses. In a study from Groningen<sup>(4)</sup> all 26 patients were willing to undergo the implant procedure again. In another study from Gothenburg<sup>(5)</sup> on 99 patients, 95% of the patients wore their prosthesis every day and 86% wore it for more than 10 hours a day.

### Implant survival

Several studies<sup>(5-10)</sup> have reported on the long term results of Vistafix prostheses. The results quoted below measures how many implants were functioning during the time of follow-up:

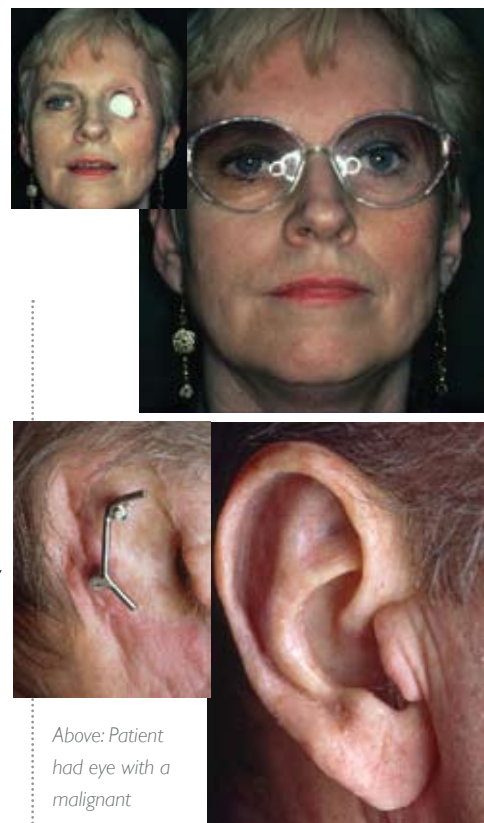
- Aural prostheses 91-100%
- Orbital prostheses 77-100%
- Nasal prostheses 76-100%

The above figures relate to implants in non-irradiated bone. In irradiated bone the results are somewhat less favourable<sup>(4,5)</sup>. The difference between the outcome in the aural and orbital/nasal region may be due to the good bone quality in the mastoid region<sup>(6)</sup>. The most common complication is soft tissue infection around the implant. The incidence of infection is lower in aural prostheses compared to the orbital and nasal prostheses, because the tissue is thin and immobile and easier to clean<sup>(6)</sup>.

### Summary

The main benefits of Vistafix treatment compared to plastic surgery are<sup>(3,11)</sup>:

- Predictable end result.
- Simpler.
- Faster physical and social rehabilitation.
- Ability to achieve bilateral symmetry.



*Above: Patient had eye with a malignant tumour removed.*

*Three implants with magnets are used to retain the eye prosthesis.*

*Below: Patient's right ear removed due to a carcinoma. During that surgery, two implants were placed for the retention of an external ear prosthesis. Six weeks later, a silicone ear prosthesis was placed.*

*All images used with the permission of Dr. A. Tjellström, Sahlgrenska Hospital, Gothenburg, Sweden.*

With these benefits in mind, a Vistafix prosthesis may restore the disfigurement resulting from cancer treatment in the head and neck region better than surgery. The specific Vistafix benefits give insight as to which patients benefit most from a prosthesis. In cases of aural or orbital deficiencies, Vistafix can provide the possibility of achieving bilateral symmetry. Fast rehabilitation is key for clients with defects preventing them from participating in social activities.



# Articles

Recent articles are summarized below.

## Craniofacial reconstructions with bone-anchored epithesis in head and neck cancer patients - a valid way back to self perception and social reintegration<sup>(9)</sup>.

This study evaluates the way back to self perception and social reintegration after head and neck cancer surgery in five patients.

### KEY STATEMENTS:

- Patients who have become disfigured from their head and neck cancer surgery may suffer from psychological trauma. This trauma can be overcome with a maxillofacial prosthesis.
- One of the great advantages of bone-anchored epithesis is the attainment of bilateral symmetry.
- Where suitably indicated, the epithesis procedure provides the patient with quick physical and social rehabilitation.

## Surgical versus prosthetic reconstruction of microtia: the case for prosthetic reconstruction<sup>(11)</sup>.

This article summarises the available treatment options for microtia.

### KEY STATEMENTS:

- Based on the author's experience with requests to improve the results of unsuccessful autogenous reconstructions,

*The beauty of the prosthesis option is that there is always hope for the patient to improve their situation rather than be resigned to the result of a single surgical effort<sup>(11)</sup>.*

patients are very concerned about facial symmetry.

- Despite having knowledge of and access to the best ear reconstructive surgeons, some parents select osseointegration over the uncertainty and prolongation of autogenous reconstruction.
- An osseointegration prosthesis requires a single surgery. Plastic surgery requires multiple surgeries - a harvesting of rib cartilage and one or more surgeries to reconstruct the site.
- During the years 1994 to 2004, our implant success rate has been 100%.
- The beauty of the prosthesis option is that there is always hope for the patient to improve their situation rather than be resigned to the result of a single surgical effort.

## Osseointegrated implants and auricular defects: a case series study<sup>(12)</sup>.

A report on the survival rate of 16 patients treated with osseointegrated auricular prostheses. The observation period ranged from 6 months to 17 years.

### KEY STATEMENTS:

- The efficacy of skin-penetrating osseointegrated implants used to restore the auricular defects in this study was excellent.
- In all patients, soft tissue inflammation resolved rapidly with resumption of appropriate daily hygiene measures, removal

of physical irritants, or with soft tissue revision.

### REFERENCES

1. Oh WS, Roumanas E, Beumer J 3rd. Maxillofacial restoration after head and neck tumor therapy. *Compend Contin Educ Dent*. 2007 Feb;28(2):70-6; quiz 77, 101.
2. Miles BA, Sinn DP, Gion GG. Experience with cranial implant-based prosthetic reconstruction. *Journal of Craniofacial Surgery* 2006 17:889-897.
3. Wagenblast J, Baghi M, Helbig M, Arnoldner C, Bisdas S, Gstöttner W, Hambek M, May A. Craniofacial reconstructions with bone-anchored epithesis in head and neck cancer patients - a valid way back to self perception and social reintegration. *Anticancer Research* 2008; 28:2349-2352.
4. Schoen PJ, Raghoebar GM, van Oort RP, Reinsema H, van der Laan BFAM, Burlage FR, Roodenburg JLN, Vissink A. Treatment outcome of bone-anchored prostheses after tumor surgery. *Cancer* Dec 2001;92(12):3045-50
5. Westin T, Tjellström A, Hammerlid E, Bergström K. Long term study of quality and safety of osseointegration for the retention of auricular prostheses. *Otolaryngology-Head and Neck Surgery* 1999; 121(1):133-143.
6. Abu-Serriah MM, McGowan DA, Moos KF, Bagg J. Outcome of extra-oral craniofacial endosseous implants. 2001; 39, 269-275.
7. Jacobsson M, Tjellström A, Fine L, Andersson H. A retrospective study of osseointegrated skin-penetrating titanium fixtures used for retaining facial prostheses. *Int J Oral Maxillofac Implants* 1992; 7: 523-528.
8. Wolfardt JF, Wilkes GH, Parel SM, Tjellström A. Craniofacial osseointegration: the Canadian experience. *Int J Oral Maxillofac Implants* 1993; 8: 197-204.
9. Roumanas E, Nishimura RD, Beumer J, Moy PK, Weinlander M, Lorant J. Craniofacial defects and osseointegrated implants: six-year follow-up report on the success rates of craniofacial implants at UCLA. *Int J Oral Maxillofac Implants* 1994; 9: 579-585.
10. Tolman DE, Taylor PF. Bone-anchored craniofacial prosthesis study. *Int J Oral Maxillofac Implants* 1996; 11: 159-168.
11. Gion GG. Surgical versus prosthetic reconstruction of Microtia: the case for prosthetic reconstruction. *Journal of Oral and Maxillofacial Surgery* 2006; 64: 1639-1654.
12. Wright RF, Zennick C, Wazen JJ, Asher E. Osseointegrated implants and auricular defects: a case series study. *Journal of Prosthodontics* 2008; 17: 468-475.

**Q** When tightening screws manually, how can we ensure the correct torque for abutment and gold screws?

**A** Use the torque wrench together with the machine screwdriver abutment to ensure the correct torque when tightening screws manually. The recommended torque levels are 20 Ncm for abutment screws and 10 Ncm for gold screws.

Answer by Martin Bryman, Cochlear BAS.

**Q** There used to be two different heights of the gold cylinder (3mm and 4mm), but now there is only a 4mm gold cylinder. Why is that?

**A** The design of the 4mm gold cylinder has been changed. The upper 1mm may now be ground down to adjust the height individually. The goal of this is to increase the flexibility of the system and decrease the number of articles our customers need to keep in stock.

Answer by Martin Bryman, Cochlear BAS.

With best wishes, your BAS R&A team; Mark Flynn, Fredrik Breitholtz, Glenn Halvarsson, Agneta Rosengren and Andre Sadeghi.

Please contact Fredrik Breitholtz at [fbreitholtz@cochlear.com](mailto:fbreitholtz@cochlear.com), if you have any further questions regarding the issues covered in this newsletter. Cochlear Bone Anchored Solutions AB, PO Box 82, 435 22 Mölnlycke, Sweden Phone +46 31 792 44 00 [www.cochlear.com](http://www.cochlear.com)