

In this issue:

- Exploring the Linear Incision Technique.
- Reviews of recent Baha articles.

Linear Incision Technique – Procedure and clinical results

In the early 1990s, a linear incision surgical technique was developed at the Radboud University Nijmegen Medical Centre. This technique simplified implant surgery by doing away with the skin flap and reducing surgery time. This article gives an overview of the technique and its clinical outcomes.

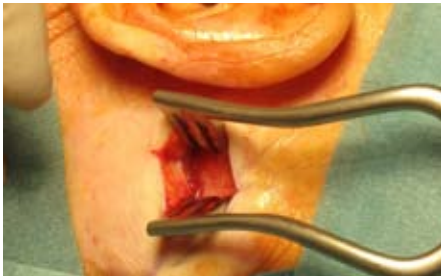


Figure 1. Exposing the implant site.

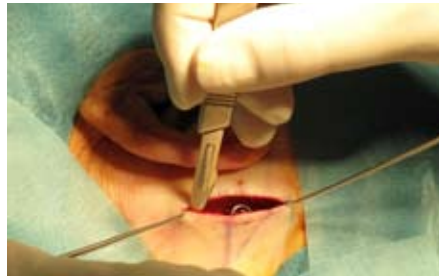

Figure 2. Tenting the skin to facilitate soft tissue reduction.

THE LINEAR INCISION TECHNIQUE

The implant site is positioned 50-55mm from the ear canal. A 30mm vertical incision is made down through the periosteum at the hairline to expose the planned implant site as shown in Figure 1. Approximately 10mm of the periosteum is removed around the site. The site is drilled and the implant is placed.

Around the incision, the soft tissue is manually reduced in the area of 60X40mm by tenting with skin hooks. As a counter pressure, a finger feels for sufficient thinning.

To further facilitate thinning, the skin is stretched along the incision and lifted slightly to achieve a flat surface along the area of reduction as illustrated in Figure 2.

The incision is sutured and compression is applied with the healing cap.

CLINICAL RESULTS

Several studies from Nijmegen and other centres have been published on the Linear Incision Technique¹⁻⁵. This summary compares the outcomes of two studies from Nijmegen^{2,3} to other long term results using traditional surgical techniques⁶⁻⁸. We have selected studies with similar length of follow-up and number of patients. Note that there may be unknown factors influencing the outcomes such as the local treatment protocol or the mix of indications. A short presentation of the studies can be found in Table 1.

COMPLICATIONS

The complications after Baha surgery include skin reactions, skin overgrowth and flap necrosis. In these complications the Linear Incision Technique compares well with results reported from other Baha surgical techniques as seen in Table 2.

IMPLANT LOSS

In Table 3 we summarize the incidence of implant loss in the studies. In total 14 implants were extruded, out of the 150 in the Nijmegen study during the follow-up period. As shown in Table 3, this compares well with the other studies.

RESULTS IN CHILDREN

The incidence of skin reactions are slightly higher in the paediatric study and similar results have been reported by other studies^{8,9}. When comparing the frequency of implant loss to other reported paediatric results⁹, we can see that they are similar (refer to Table 4). However, compared to studies on adults, implant loss is more frequent in children. The authors of the original paper conclude that the Linear Incision Technique is useful in both children and adults. However, they stress the need for frequent follow-ups in children.

BENEFITS OF LINEAR INCISION TECHNIQUE

The exclusion of the skin flap avoids the risk of flap necrosis, and, in the hands of the experienced surgeon, reduces the time in surgery. The

Study incident	Nijmegen ²	Chester ⁶	Los Angeles ⁷
Implants	150	177	149
Time of follow-up	0-10,5 Y	4-14 Y	0-4 Y
Patient age	4-82 Y	4-85 Y	3-88 Y

Table 1. Overview of the compared outcome studies.

Complication (%)	Nijmegen ²	Chester ⁶	Los Angeles ⁷
Skin reaction => 2	21	28	Not reported
Skin overgrowth	6,0	8,5	7,4
Flap necrosis	0	2,2	0,7

Table 2. Reported complications.

Implant loss (%)	Nijmegen ²	Chester ⁶	Los Angeles ⁷
Spontaneous loss	2,0	13,6	0,7
Trauma	3,3	3,9	0
Infection	0,7	0,6	2,7
Chronic pain	2,0	2,3	-
Other	1,4	-	-
Total	9,4	20,4	3,4

Table 3. Causes of implant loss.

Implant loss (%)	Nijmegen ³	Birmingham ⁸
Spontaneous loss	9,3	3,5
Trauma	2,3	2,2
Infection	3,9	8,3
Other	0,8	-
Total	16,3	14,0

Table 4. Causes of implant loss in paediatric cases

technique is relatively simple and the recovery of the patients has been uneventful in the reviewed studies. Comparing the Linear Incision Technique with other reported long-term results shows that the outcome is equivalent to other Baha surgical techniques.

CONCLUSION

There are specific benefits with the linear technique that should be considered when selecting which technique to use. Or as Professor Cremers puts it: "If you complicate your surgery, you will have more complications."

Materials on the Linear Incision Technique are now available from Cochlear.



Articles

Recent articles are summarized below.

Bone-anchored hearing aid: a single stage procedure in children.¹⁰

A review of 30 consecutive surgeries in Glasgow on children aged 3-15 years* that were fitted with the Baha over a period from 1997-2005. All surgeries were performed as single stage procedures.

KEY STATEMENTS:

- All children in the study had successful osseointegration.
- Early complications of infection at the abutment occurred in two children. These were successfully treated with topical antibiotic ointment.
- The main advantage of performing the surgery in a single stage is the avoidance of a second anaesthetic for abutment fitting.

Experience with the longer (8.5 mm) abutment for bone anchored hearing aid.¹¹

A retrospective case review of 111 patients who received the 8.5mm abutment was done. More than 90% of these patients received the longer abutment as a treatment for persisting soft tissue problems. Average follow up was 21 months.

KEY STATEMENTS:

- 80 of the 81 patients with significant soft tissue problems that received the longer abutment required no further surgical intervention.
- Of the patients that had soft tissue overgrowth, 29.3% had either partial or complete skin graft failure at their primary surgery. There seems to be an association between initial skin graft failure and subsequent soft tissue problems.
- The use of a longer abutment for patients with soft tissue overgrowth has been successful after topical management and surgical intervention have failed.

Q A client would like to listen to her MP3 player in stereo (Baha on one side and ear-phone on the other), but the audio adapter does not have an input for earphones. Is it possible to solve this?

A Yes, this can be achieved by plugging a 3.5mm stereo splitter (image on right) into the MP3 player. Then place the audio adaptor

"80 of the 81 patients with significant soft tissue problems that received the longer abutment required no further surgical intervention"¹¹

Patient quality of life with Baha in Glasgow: 10 year experience.¹²

A retrospective study to evaluate the quality of life with Baha using the Glasgow benefit inventory. 60 patients were identified and a questionnaire was sent out. The response rate to the questionnaire was 63%

KEY STATEMENTS:

- 91% of the patients reported that the Baha functioned very well or excellently when talking to one person. In a group situation this decreases.
- 75% of Baha users reported their Baha to be generally better than their previous conventional hearing aid.
- After discontinuing usage of conventional hearing aids, 68% of Baha users reported a reduction in ear infections due to improved ventilation of the external auditory canal.
- 68% of Baha users reported that their Baha was cosmetically superior and easier to handle than their previous device.
- The median total Glasgow benefit inventory score was +33,3. This score compares favourably with earlier published studies.

Can keratinocytes cause failure of osseointegration?¹³

This report concerns two implants: one with osseointegration failure and the other explanted for other reasons. Both implants were examined by transmission electron microscopy and histopathological analysis. Keratinocytes (basal cells commonly found in the outermost layer of the skin) were found in the both of the implant-bone interfaces.

KEY STATEMENTS:

- Our findings suggest that keratin may play a role in understanding osseointegration failure.
- Activation of keratinocytes may be caused by an infective or inflammatory process of the skin flap. Over time, this could lead to bone resorption and migration of keratinocytes to the

bone-titanium interface.

- One must question whether keratinocytes cause osseointegration failure or whether they are a by-product of this process. How and why keratinocytes implant at the bone-titanium interface can only be hypothesised.

* In the U.S. the FDA has cleared implantation for children aged 5 and older.

REFERENCES

1. van der Pouw CT, Mylanus EA, Cremers CW. Percutaneous implants in the temporal bone for securing a bone conductor: surgical methods and results. *Ann Otol Rhinol Laryngol.* 1999 Jun;108(6):532-6.
2. de Wolf MJ, Hol MK, Huygen PL, Mylanus EA, Cremers CW. Clinical outcome of the simplified surgical technique for Baha implantation. *Otol Neurotol.* 2008; 29(8):1100-8.
3. de Wolf MJ et al. Nijmegen results with application of a Bone-Anchored Hearing Aid in children: Simplified Surgical Technique *Ann Otol Rhinol Laryngol.* 2008; 117(11):805-14.
4. Bovo R. Simplified technique without skin flap for the bone-anchored hearing aid (Baha®) implant *Acta Otorhinolaryngol Ital* 2008;28:252-255.
5. Wilkinson EP, Luxford WM, Slattery WH, De la Cruz A, House JW, Fayad JN. Single vertical incision for Baha implant surgery: Preliminary results. *Otolaryngology-Head and Neck surgery* 2009, 140(1) 573-578.
6. Badran K, Arya AK, Bunstone D, Mackinnon N. Long term complications of bone anchored hearing aids: a 14 year experience. *The Journal of Laryngology & Otology* 2008: 1-7.
7. House JW, Kutz JW. Bone anchored hearing aids: Incidence and Management of postoperative complications. *Otology & Neurotology* 2007;28:213-217.
8. McDermott AL, Williams J, Kuo M, Reid A, Proops D. The Birmingham paediatric bone anchored hearing aid programme: A 15 year experience. Thesis Radboud University Nijmegen Medical Centre, Nijmegen, the Netherlands.
9. Lloyd S, Almeyda J, Sirimanna KS, Albert DM, Bailey CM. Updated experience with the bone-anchored hearing aids in children. *J Laryngol Otol* 2007;121:826-31.
10. Ali S, Hadoura L, Carmichael A, Geddes NK. Bone-anchored hearing aid: a single-stage procedure in children. *Int J Pediatr Otorhinolaryngol.* 2009 May 25. [Epub ahead of print].
11. Monksfield P, Ho EC, Reid A, Proops D. Experience with the longer (8.5 mm) abutment for Bone-Anchored Hearing Aid. *Otol Neurotol.* 2009 Apr;30(3):274-6.
12. Mace AT, Isa A, Cooke LD. Patient quality of life with bone-anchored hearing aid in Glasgow: 10-year experience. *J Laryngol Otol.* 2009 May 20:1-5. [Epub ahead of print].
13. Khwaja S, Curry A, Chaudhry IH, Green KM. Can keratinocytes cause failure of osseointegration? *J Laryngol Otol.* 2008 Dec 9:1-4. [Epub ahead of print].

in one of the outlets and the headphone in the other. You can buy the splitter in any electronics store.

Answer by André Sadeghi, Cochlear.



3.5mm stereo splitter

With best wishes, your BAS R&A team; Mark Flynn, Fredrik Breitholtz, Glenn Halvarsson, Agneta Rosengren and Andre Sadeghi.

Please contact Fredrik Breitholtz at fbreitholtz@cochlear.com, if you have any questions regarding the content of this newsletter.

Cochlear Bone Anchored Solutions AB, PO Box 82, 435 22 Mölnlycke, Sweden Phone +46 31 792 44 00 www.cochlear.com